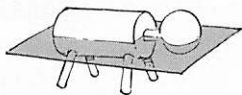
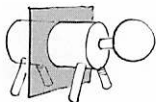


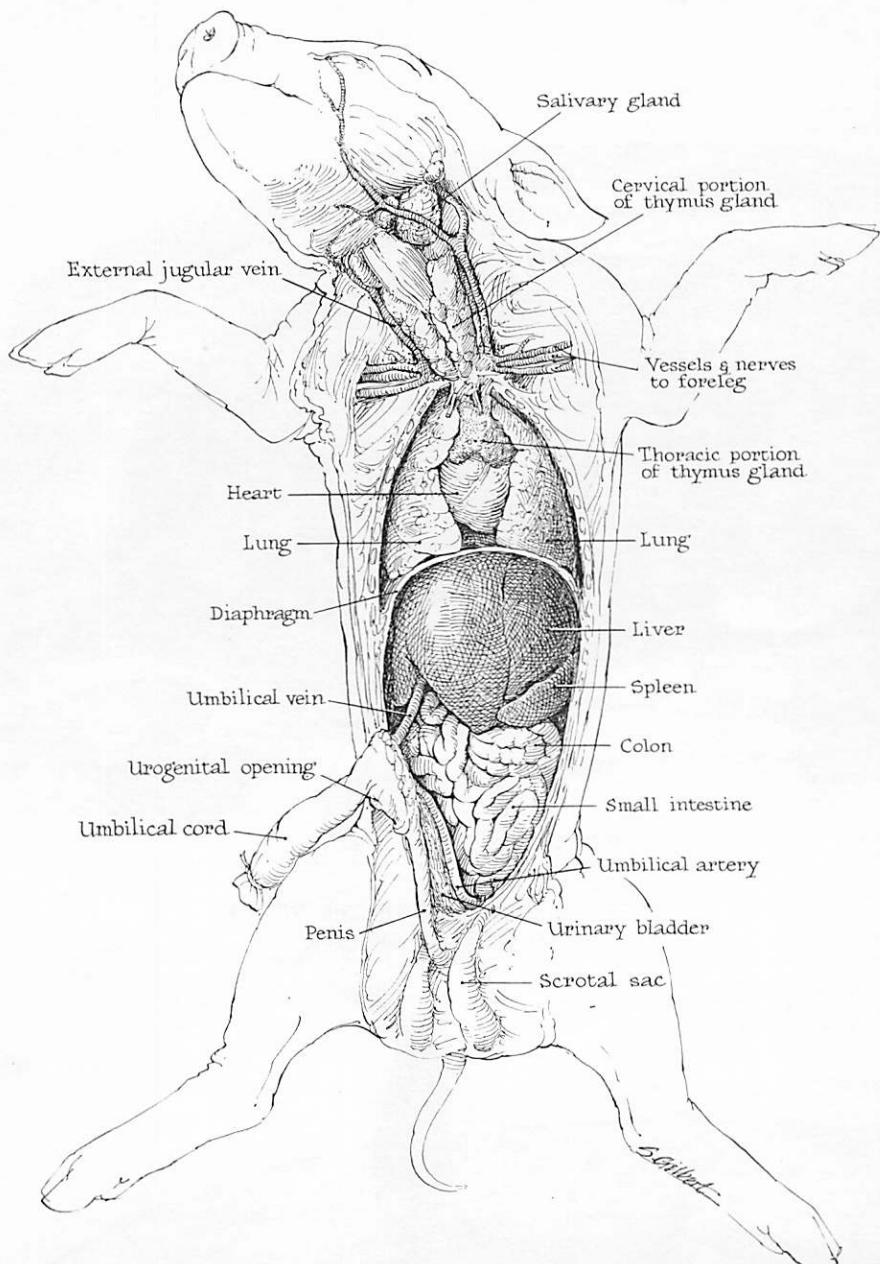
Median sagittal plane

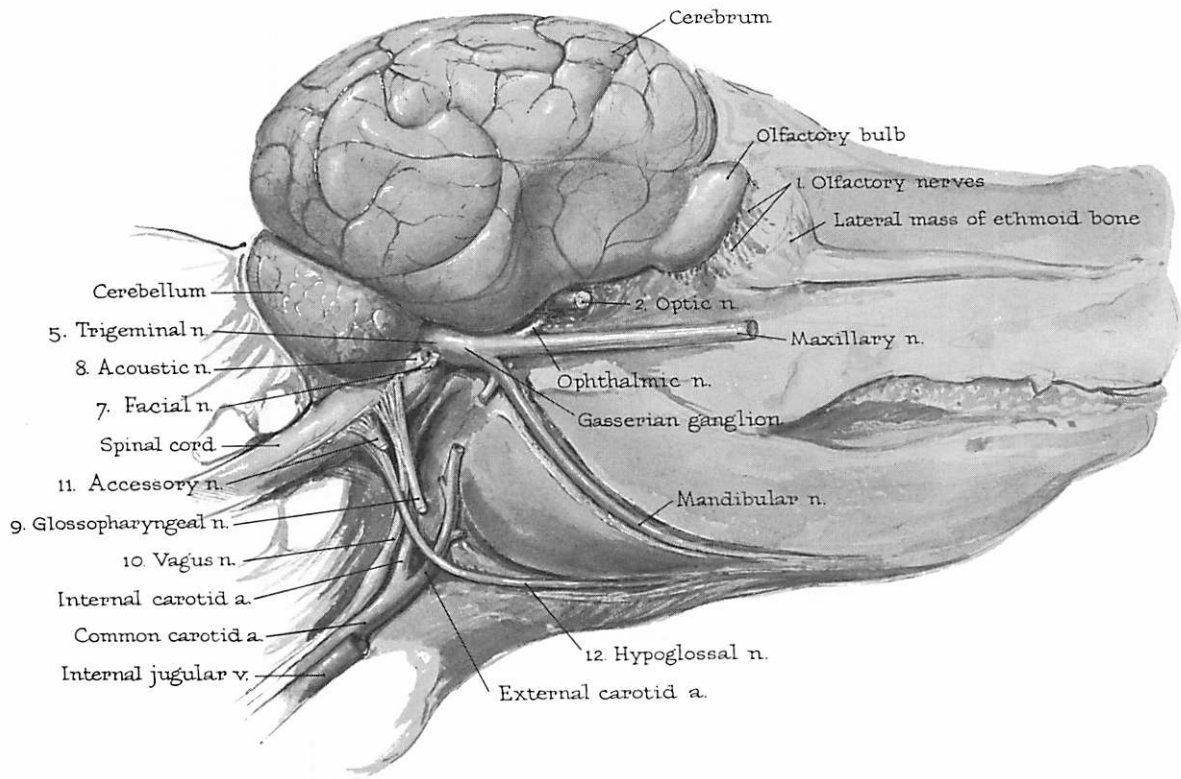


Horizontal or frontal plane

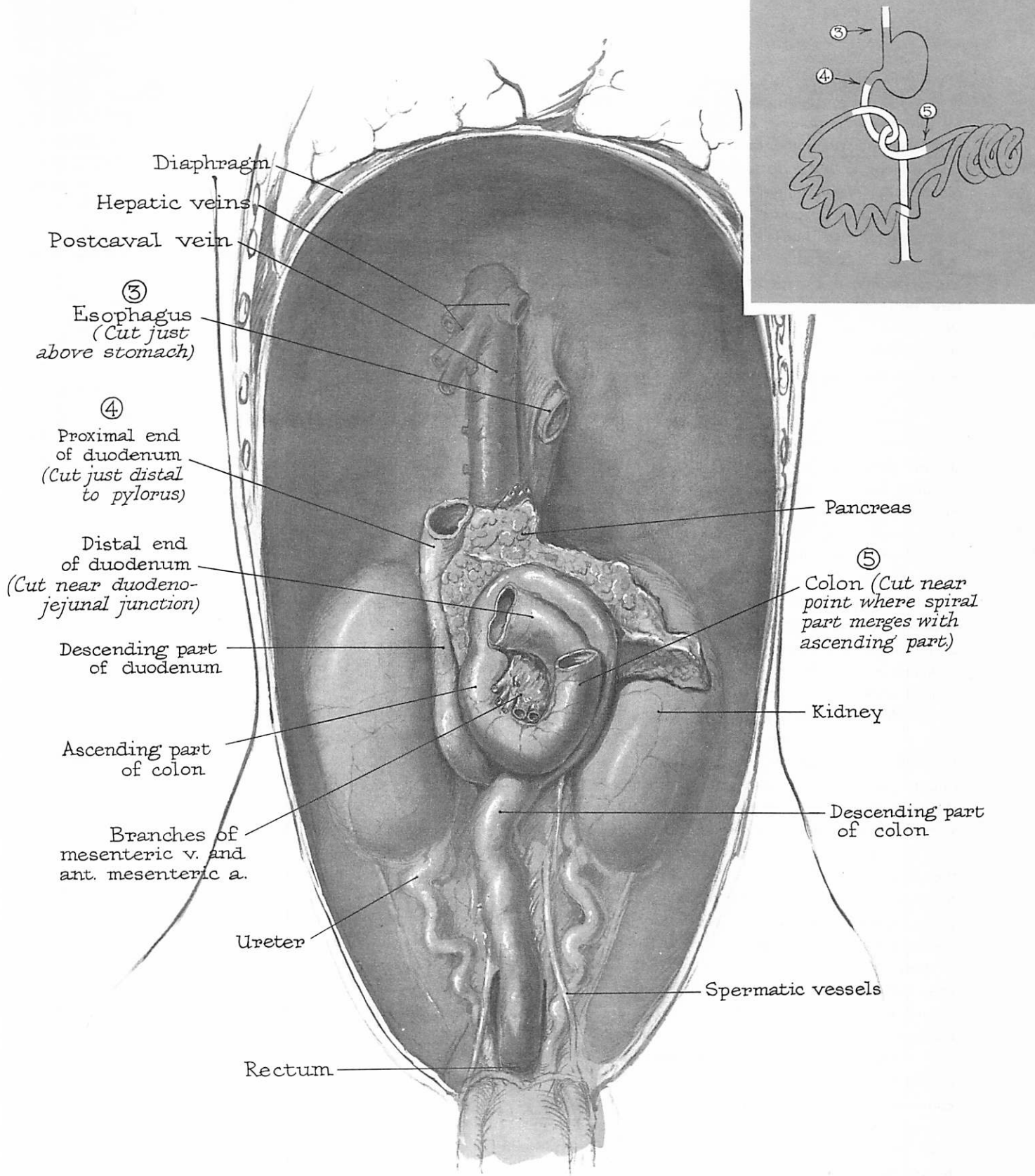


Transverse or cross plane

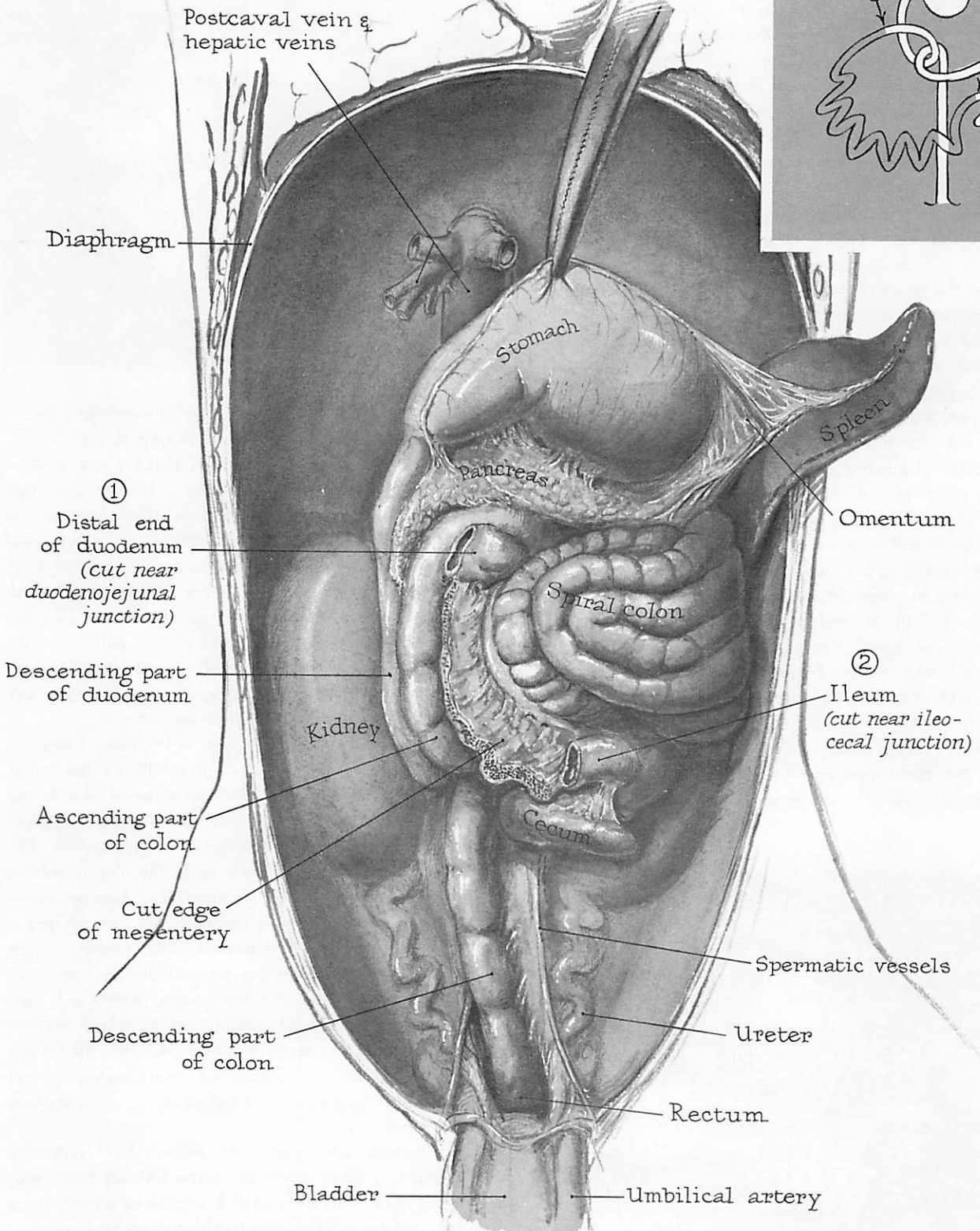
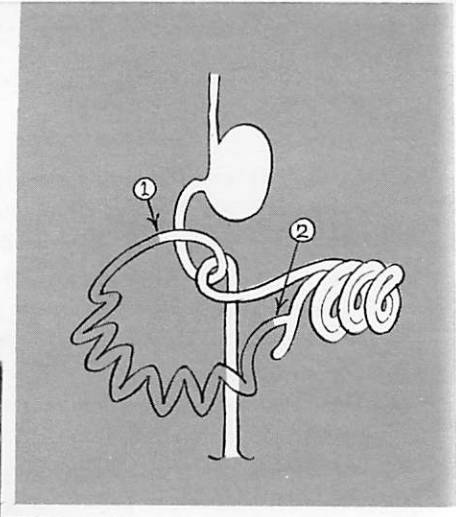




LATERAL VIEW OF THE BRAIN AND CRANIAL NERVES IN THE FETAL PIG



ABDOMINAL VISCERA
Deep dissection



ABDOMINAL VISCERA
Superficial dissection